

Optimization of Coronary Stents Using High-Pressure-Balloon Inflations: Fighting With a Catastrophe

C.GRAIDIS, D.DIMITRIADIS, A.NTATSIOS, V.KARASAVVIDIS,
V.PSIFOS

EUROMEDICA – KYANOUS STAVROS HOSPITAL
THESSALONIKI, GREECE

Endovascular Cardiac Complications
15-17 JUNE 2011-LAUSANNE, SWITZERLAND



HELLENIC INSTITUTE OF CARDIOVASCULAR DISEASES

Background

Iatrogenic coronary perforation complicates 0.1-0.8% of percutaneous coronary interventional procedures and is associated with high mortality and morbidity.

When coronary perforation occurs, it may rapidly result in cardiac tamponade, myocardial infarction or death, hence prompt treatment is required.

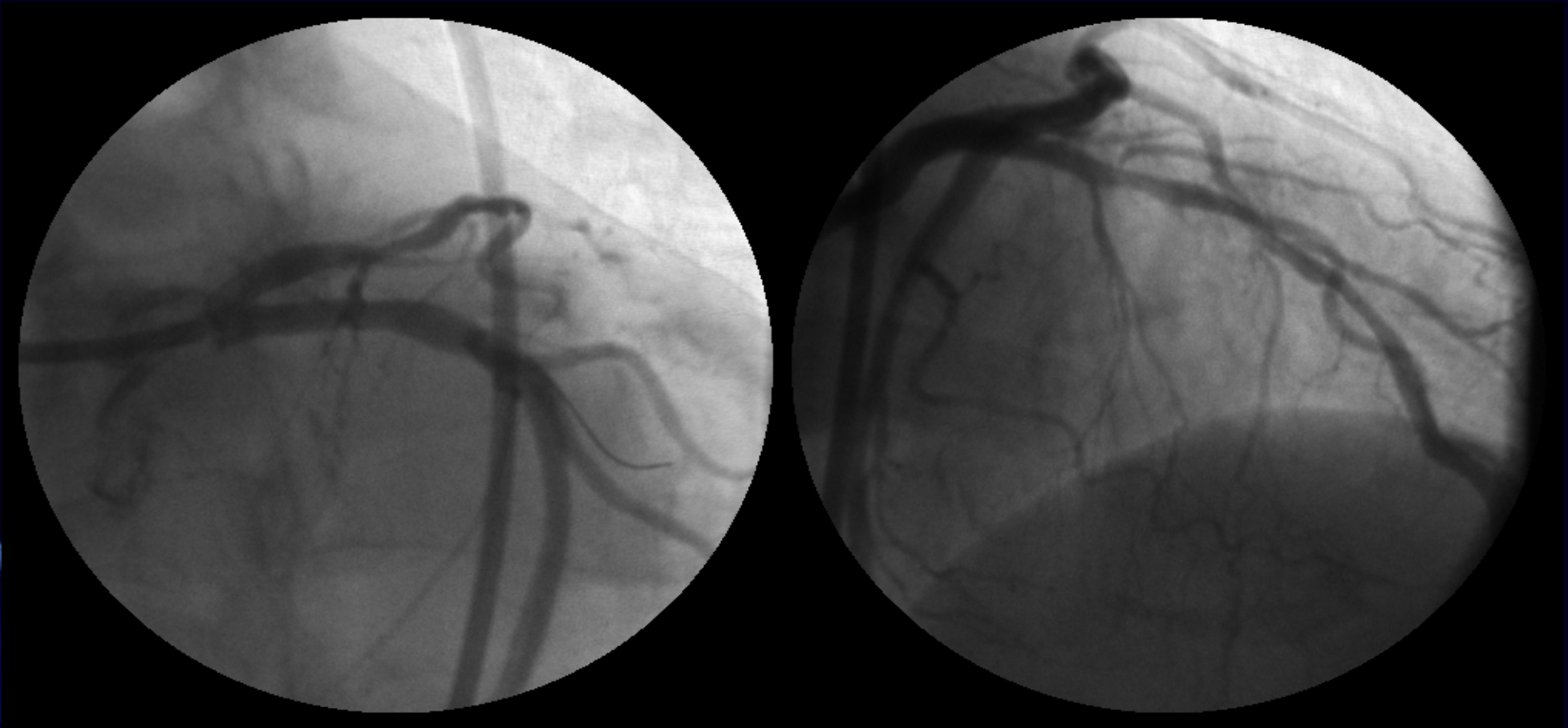

CASE PRESENTATION

- 72 y.o female.
- Risk factors for IHD: Hypertension, Dyslipidaemia.
- DHx: Aspirin, Clopidogrel, statin, β -blocker, nitrate.
- Referred for cardiac catheterisation because of exertional angina and a strongly positive Exercise Tolerance Test.



Diagnostic coronary angiogram



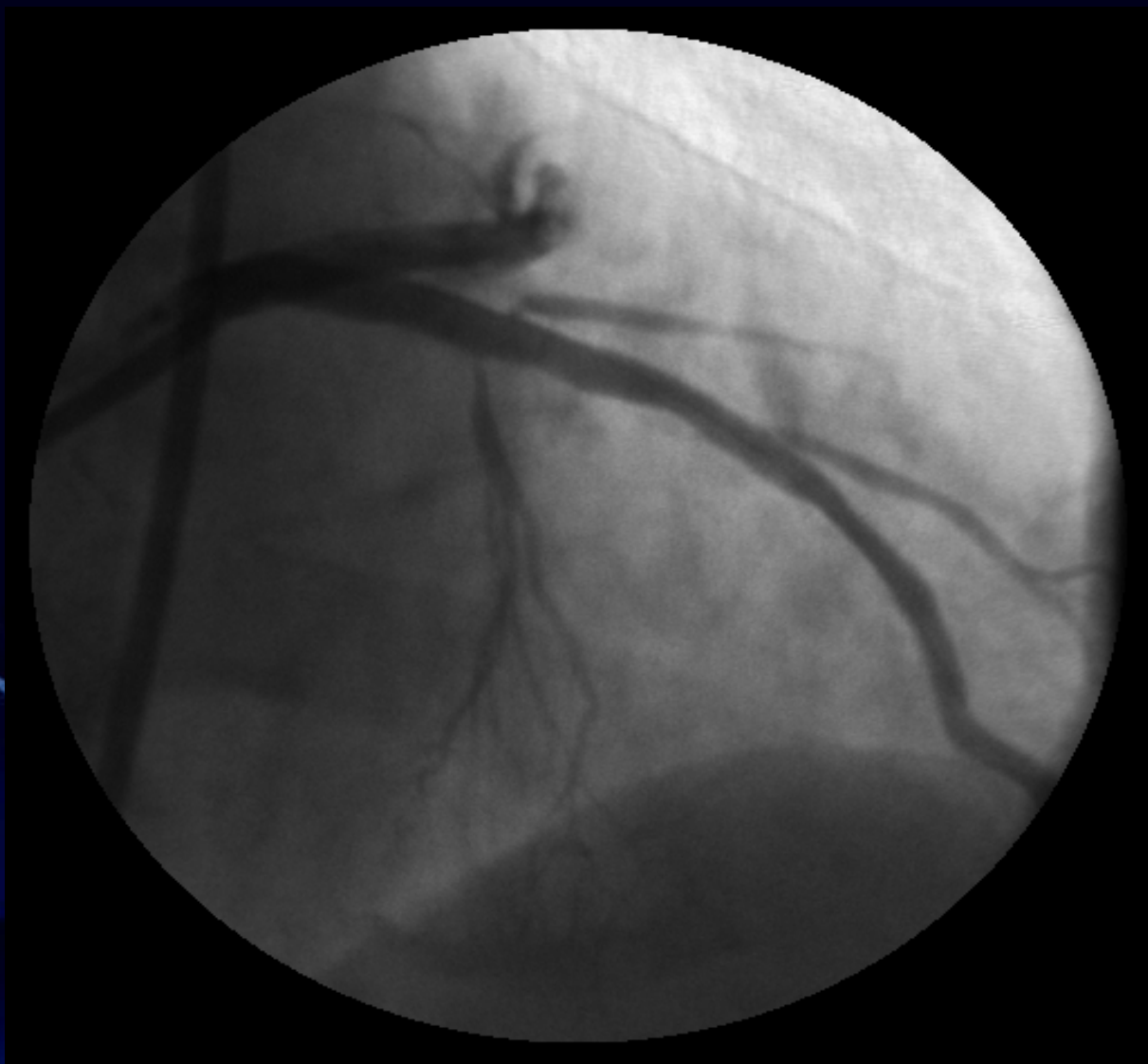LMS: Normal

LAD: Severe proximal and mid-vessel disease

Cx: Normal RCA: Mild irregularities



HELLENIC INSTITUTE OF CARDIOVASCULAR DISEASES



- Heparin 6.000 IU.
- Two overlapping 3.0x32 and 3.5x24mm Taxus stents were directly implanted.
- Due to underexpansion of the distal stent, we decided to perform postdilatation.



What balloon would you choose for post-dilatation?


1. Non-compliant balloon 3.5mm?

2. Non-compliant balloon 3.0mm?

3. Balloon of the proximal stent (3.5mm)?



Immediately after postdilatation with the 3.5x24mm balloon (of the proximal stent) at 16 Atm...

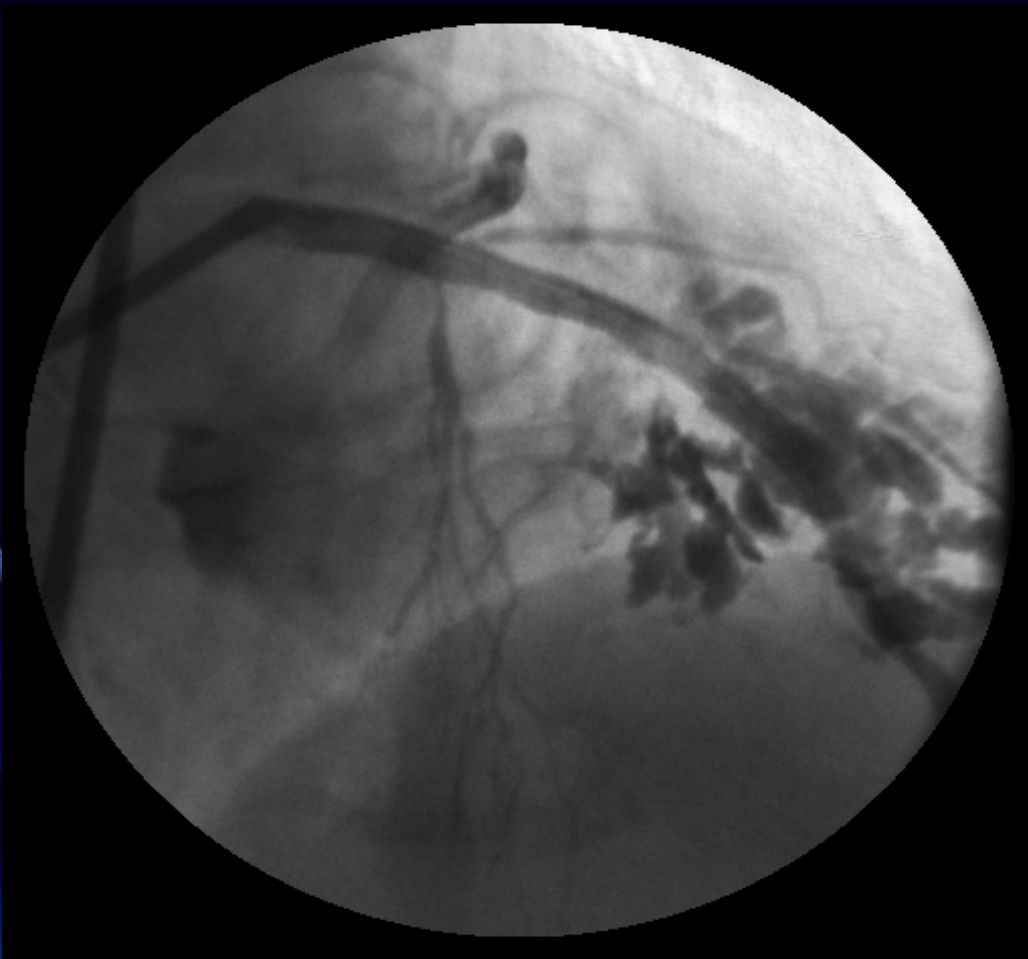


Sudden cardiovascular collapse



HELLENIC INSTITUTE OF CARDIOVASCULAR DISEASES

Severe perforation of the LAD with contrast extravasation (Ellis type III perforation)



- The patient developed chest pain and dyspnoea.
- Blood pressure dropped to 74/52mmHg – cardiac tamponade.



How would you manage this complication?

- 1. Call the surgeons**
- 2. Balloon inflation, emergent pericardiocentesis, reversal of heparine.**
- 3. Covered stents.**

OR....





HELLENIC INSTITUTE OF CARDIOVASCULAR DISEASES

Management of Coronary Perforation

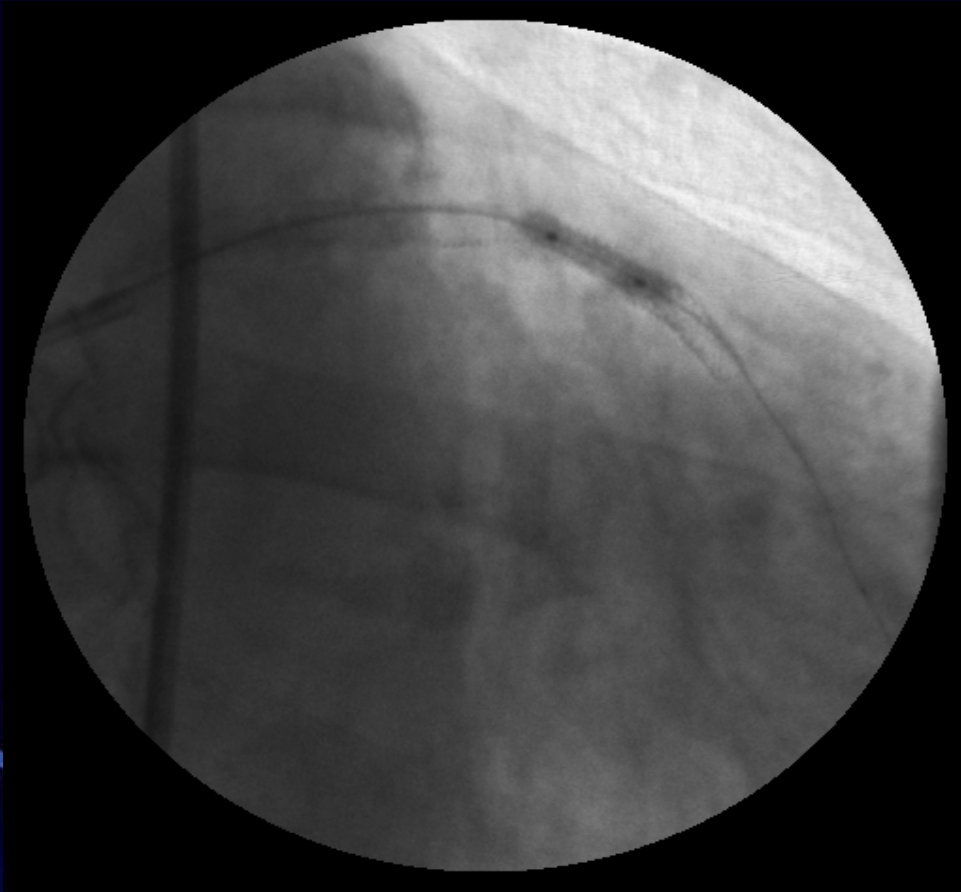Hemodynamic Support

- Volume, Inotropes
- Pericardiocentesis
- IABP

Seal Perforation

- Reverse heparin
- Balloon occlusion
- Platelets (abciximab)
- Embolization (coil, gel foam, thrombin)
- Covered stent
- Surgery

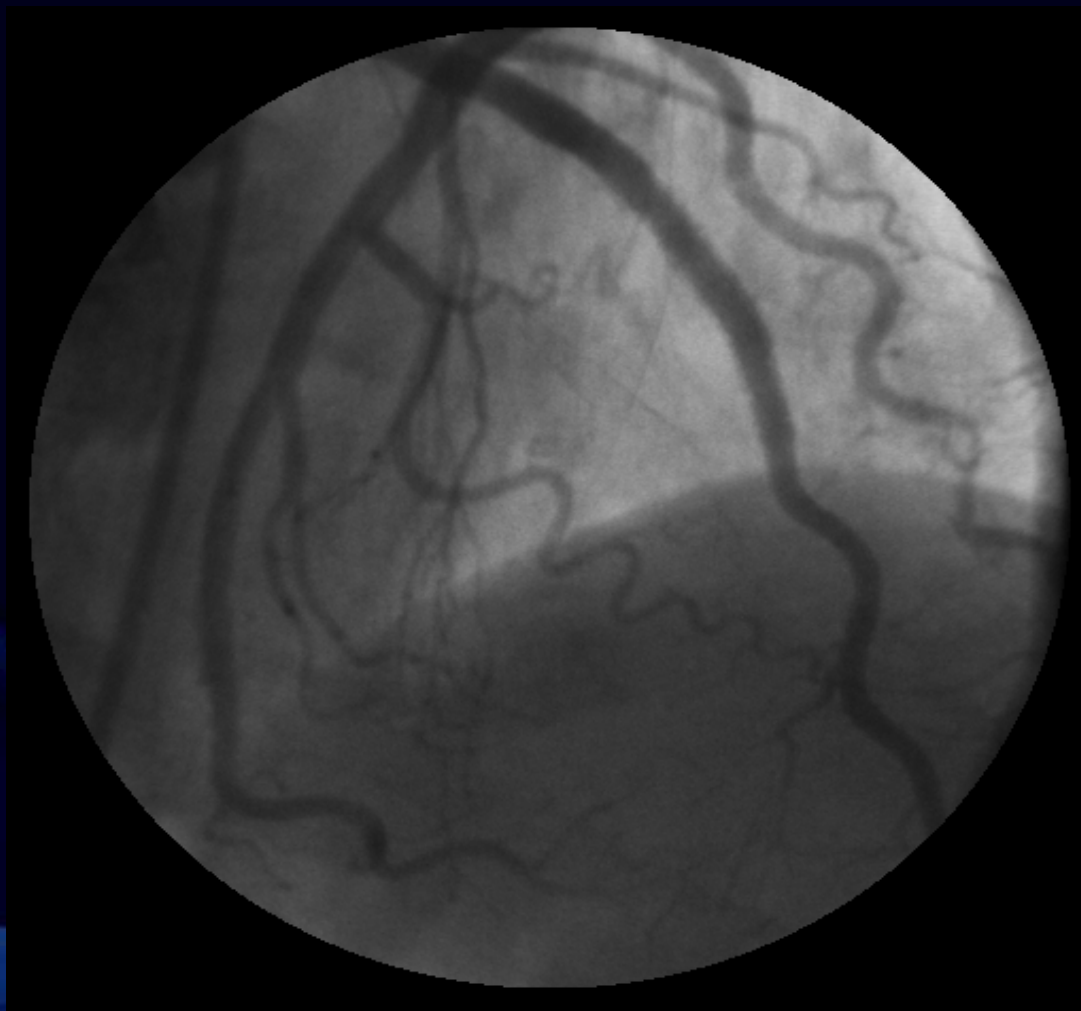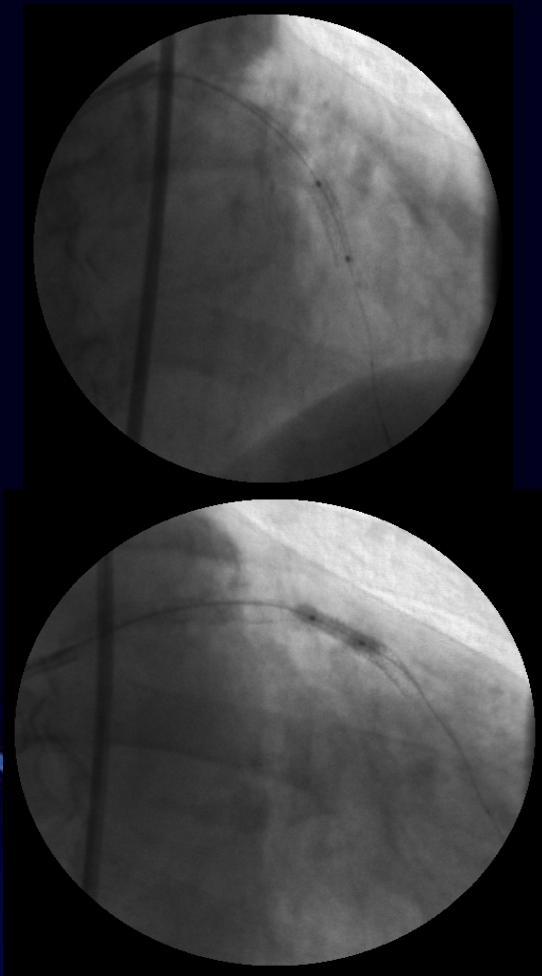




- Prolonged balloon inflation to stop the leakage.
- Emergent Pericardiocentesis .
- Blood pressure increased to 94/72mmHg.

Initial balloon dilatation can be done just at or proximal to the site of dye extravasation (many Type I and II perforations may seal off with prolonged balloon inflation alone but significant risk of late tamponade requires vigilant monitoring).



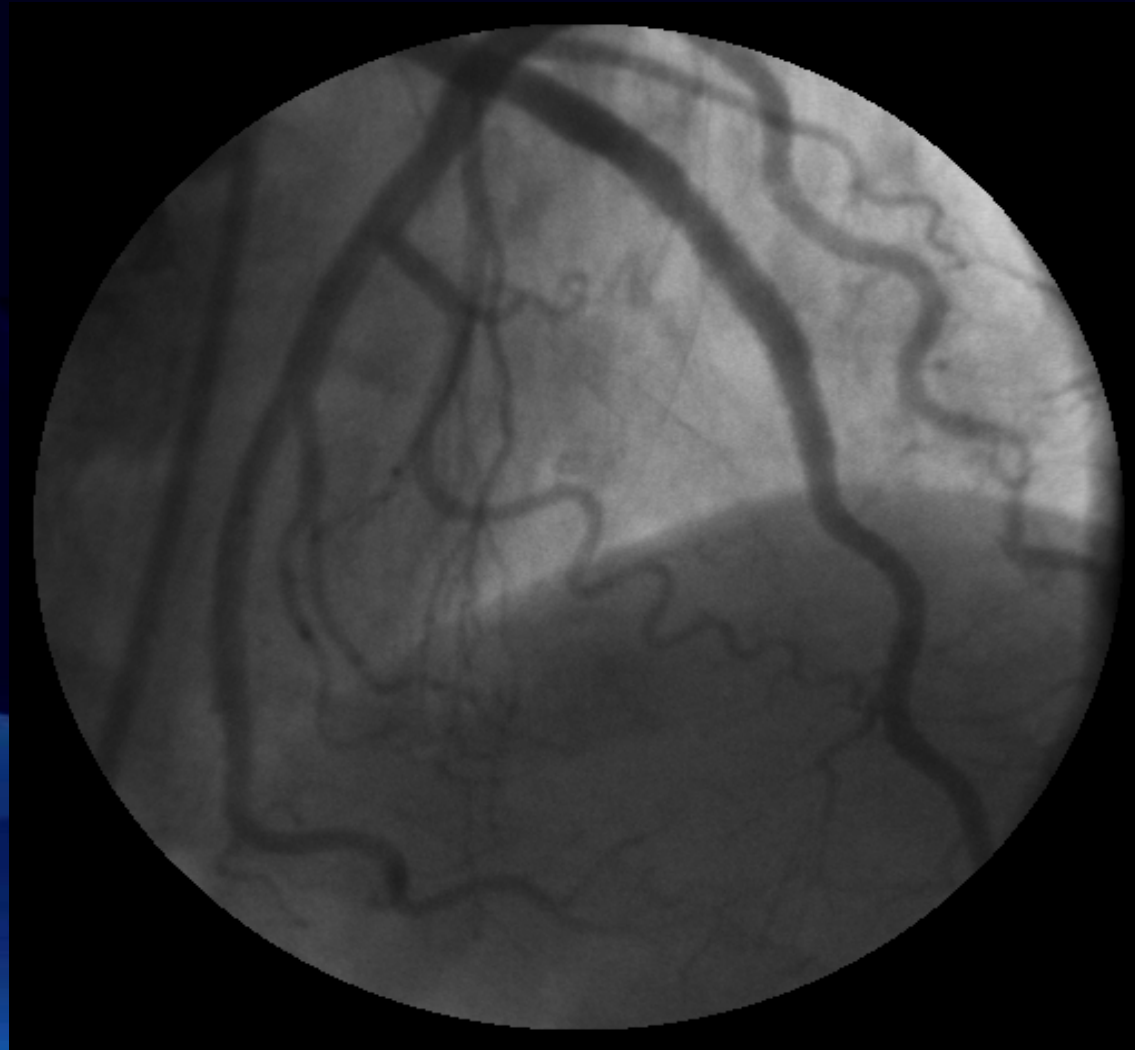

Two PTFE covered stents 3.0x16 and 3.5x12mm (Jostent graftmaster) were deployed (Single guiding catheter used- Leak sealed, anticoagulation not reversed)



HELLENIC INSTITUTE OF CARDIOVASCULAR DISEASES

Coronary angiography 1 hr later, showing successful sealing of the perforation.



HELLENIC INSTITUTE OF CARDIOVASCULAR DISEASES



- **Peak CK after the procedure was 450 U/L.**
- **The patient was discharged five days later and was advised to continue dual antiplatelet therapy indefinitely.**
- **Type III coronary artery perforations can be successfully managed by percutaneous methods.**



PTFE COVERED STENT



The Jomed Covered Stent Graft is a balloon expandable, slotted tube stent comprising a layer of ultra-thin (75 μ m) PTFE graft material sandwiched between two stents of reduced wall thickness.




Shortening on expansion < 3%. Mounted profile 1,6mm.

High pressure inflation (16 to 20Atm).



For most type III perforation, lower pressure balloon inflation is essential to prevent further leakage, tamponade or even death and should not be interrupted for a relatively long time.



Double guiding catheter technique

The double guiding catheter technique gives the operator much enough easiness and time to deliver PTFE-covered stent while keeping the patient hemodynamically stable.

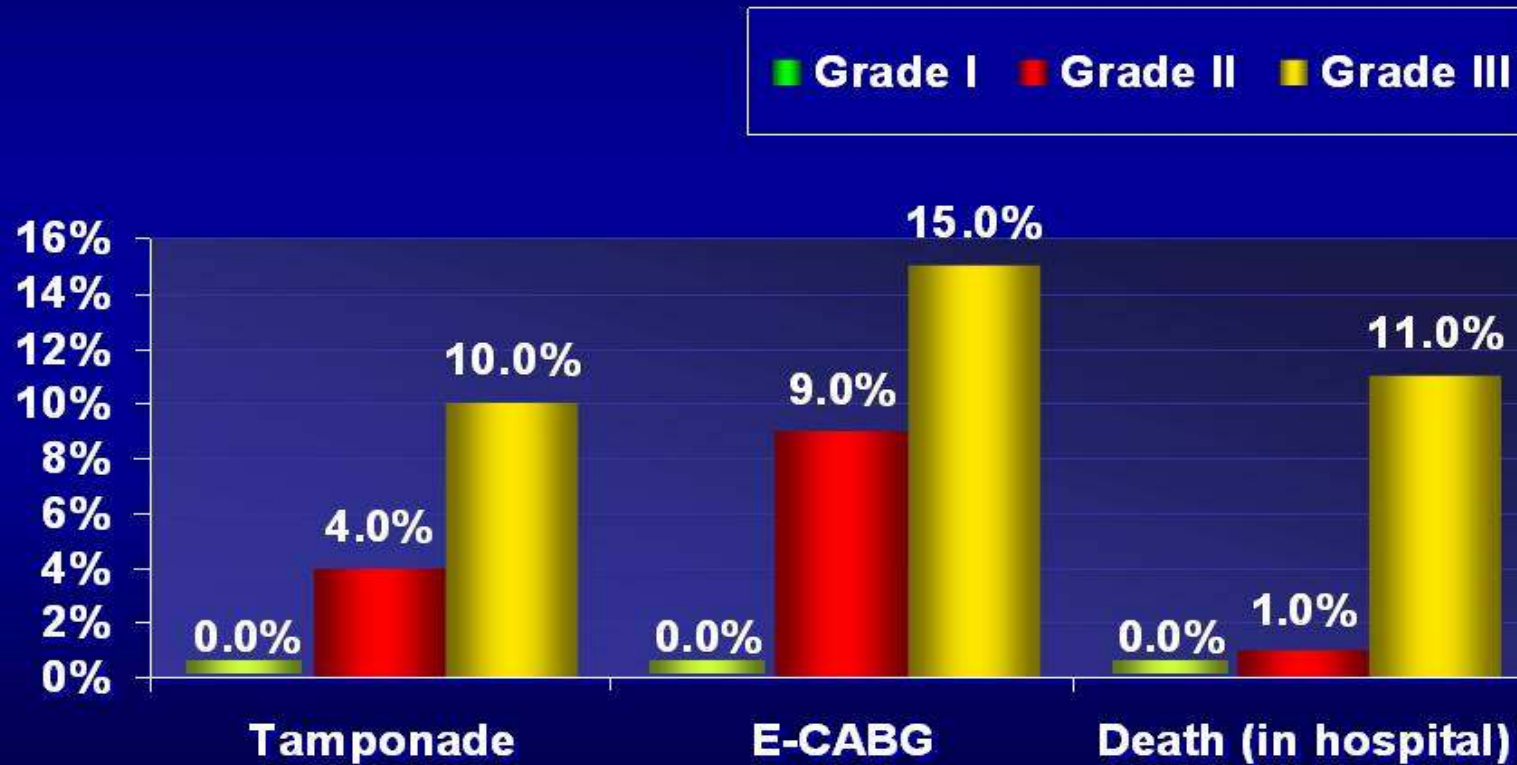


Ellis Classification

- **Grade I:** Extraluminal crater without extravasation
- **Grade II:** Pericardial or myocardial blush without contrast extravasation
- **Grade III:** Extravasation through frank (>1mm) perforation or cavity spilling into an anatomic cavity chamber



Perforation Grade and Outcome

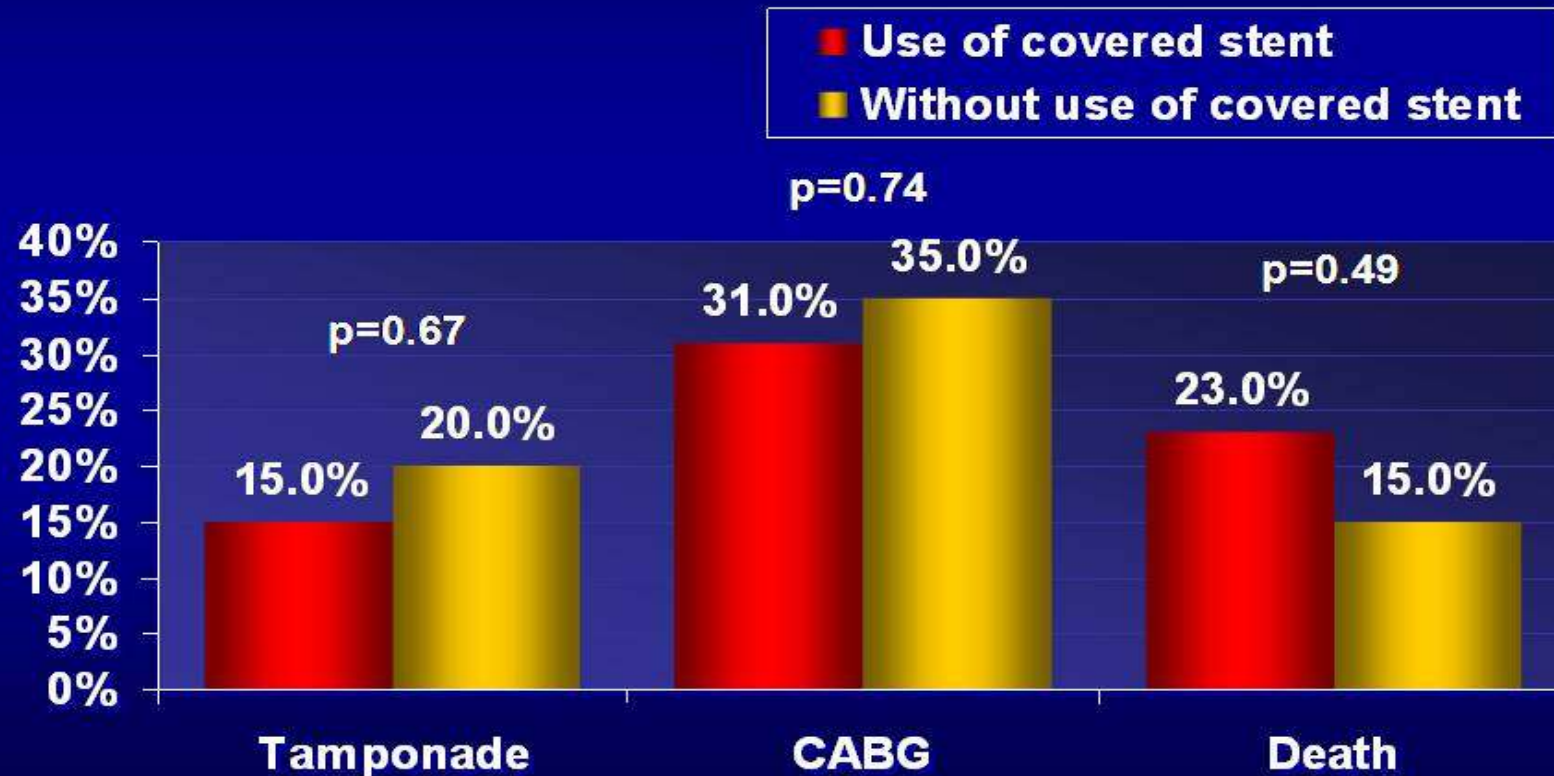


Javaid. Am J Cardiol 2006;98:911-914



Outcomes After Perforation

(May 1996-May 2005)



72 perforations/38559 cases =0.19%

Javaid. Am J Cardiol 2006;98:911-914



HELLENIC INSTITUTE OF CARDIOVASCULAR DISEASES

in coronary perforations during percutaneous interventions, today coated stent implantation seems to be the first choice in treatment of coronary perforation or training and appear to offer the best treatment option for acute perforations.

CONCLUSIONS

- ✓ In coronary perforations during percutaneous interventions, today coated stent implantation seems to be the first choice in treatment of coronary perforation considering the high mortality and morbidity rate of surgery.
- ✓ PTFE-covered stent implantation is easy, rapid and appears to offer the best treatment option for acute perforations.

